

Neurological Assessment

Lecture 8

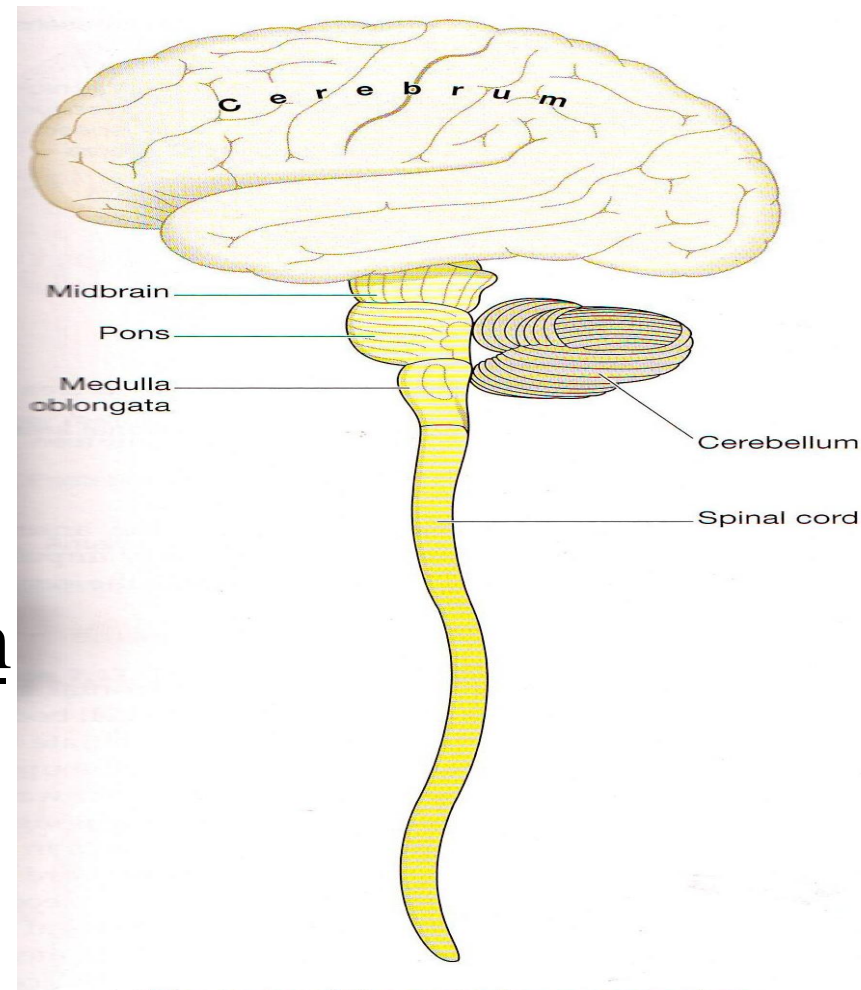
Nervous System

Central Nervous System

- Brain
- Spinal cord

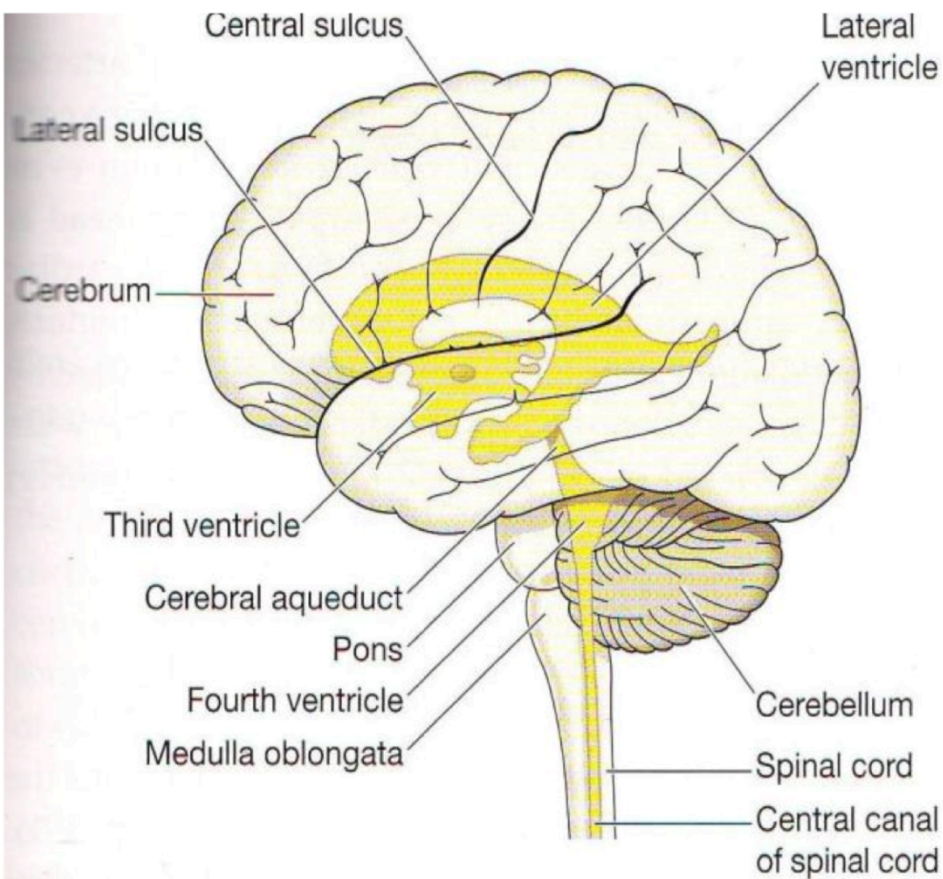
Peripheral Nervous System

- Cranial nerves
- Spinal nerves

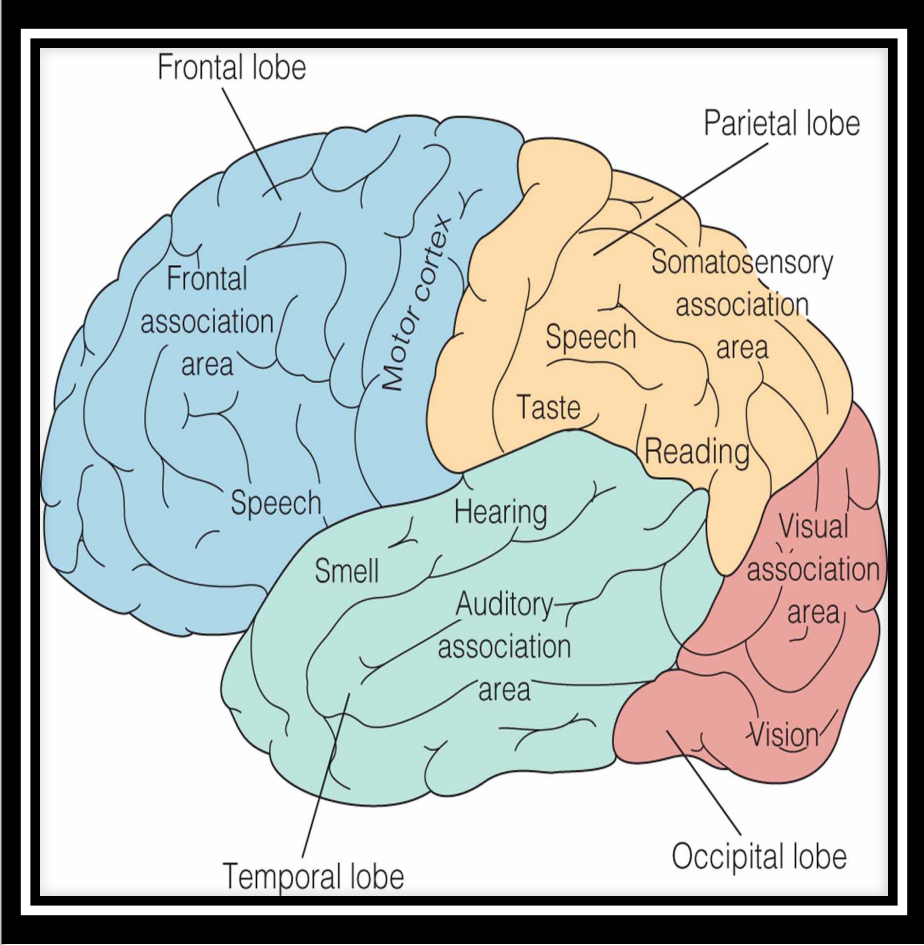


The parts of the central nervous system.

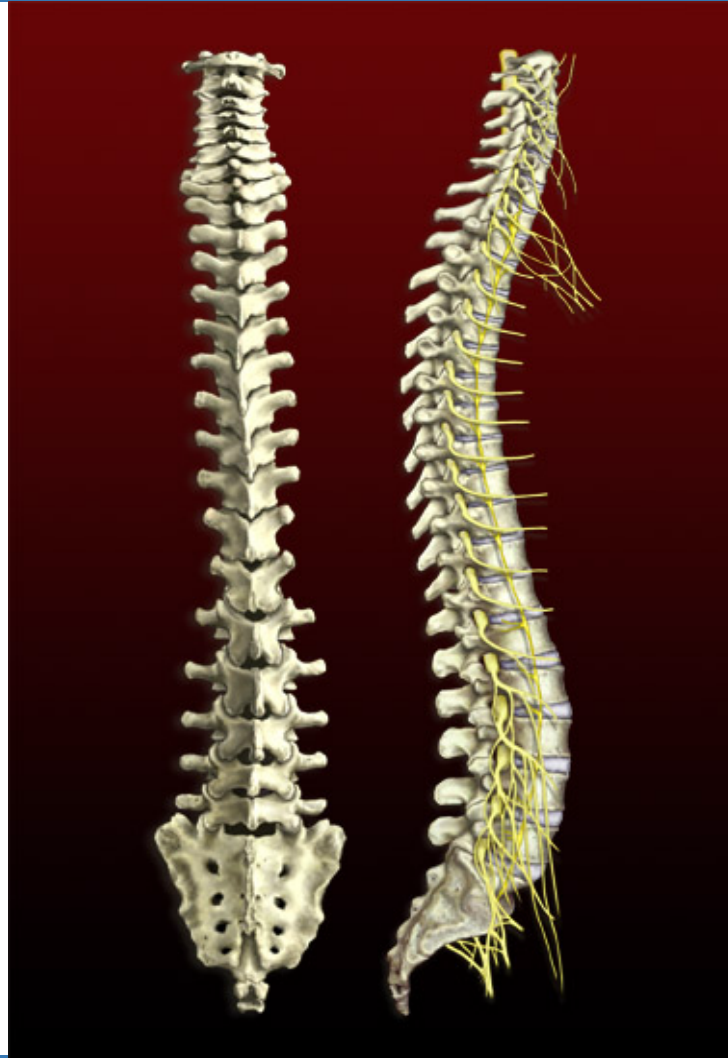Central Nervous System-Brain



The positions of the ventricles of the brain (in yellow) superimposed on its surface. Viewed from the left side.



Central Nervous System-Spinal Cord



Peripheral Nervous System-12 Pairs of Cranial Nerves

- Originate in the brain
- Control many activities in the body
- Take impulses to and from the brain

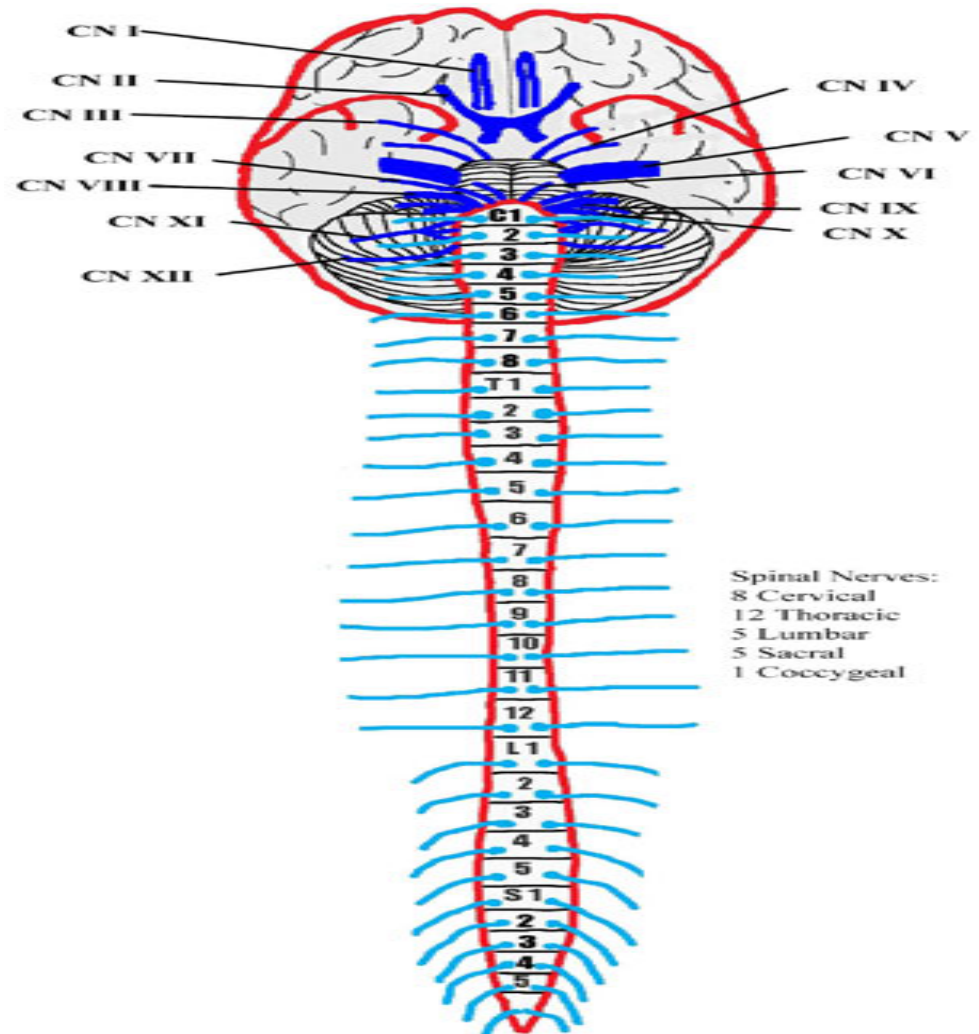


Figure 24.4 Cranial nerves and their target regions. (Sensory nerves are shown in blue; motor nerves, in red.)

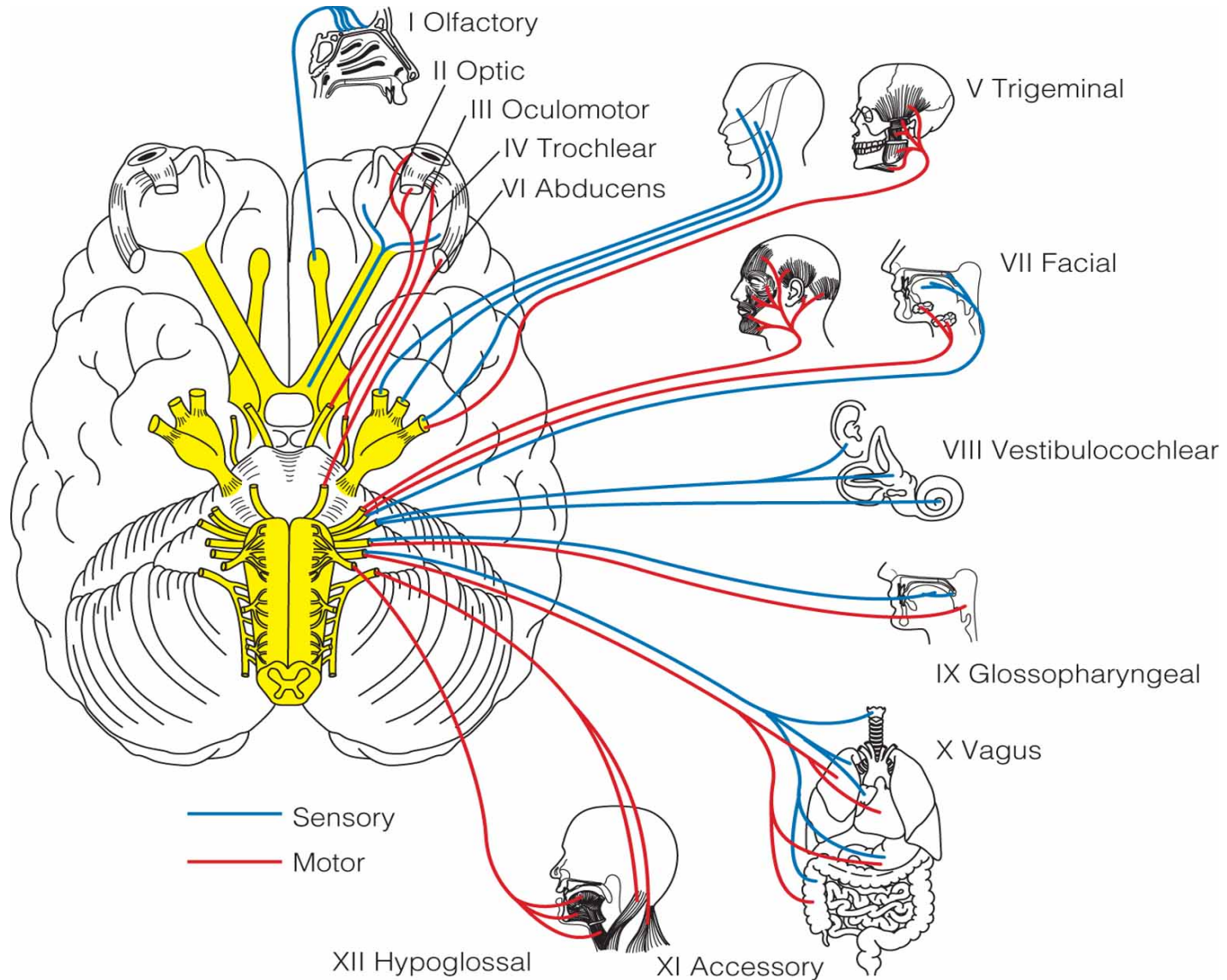
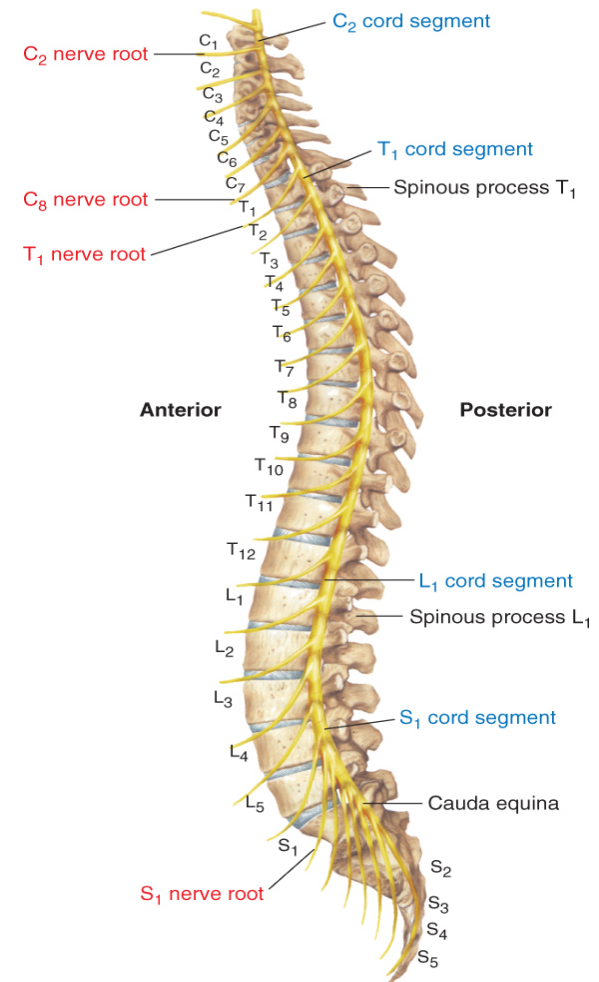


Table 24.1 Cranial Nerves

NAME	NUMBER	FUNCTION	ACTIVITY
Olfactory	I	Sensory	Sense of smell.
Optic	II	Sensory	Vision.
Oculomotor	III	Motor	Pupillary reflex, extrinsic muscle movement of eye.
Trochlear	IV	Motor	Eye-muscle movement.
Trigeminal	V	Mixed	<i>Ophthalmic branch:</i> Sensory impulses from scalp, upper eyelid, nose, cornea, and lacrimal gland. <i>Maxillary branch:</i> Sensory impulses from lower eyelid, nasal cavity, upper teeth, upper lip, palate. <i>Mandibular branch:</i> Sensory impulses from tongue, lower teeth, skin of chin, and lower lip. Motor action includes teeth clenching, movement of mandible.
Abducens	VI	Mixed	Extrinsic muscle movement of eye.
Facial	VII	Mixed	Taste (anterior two thirds of tongue). Facial movements such as smiling, closing of eyes, frowning. Production of tears and salivary stimulation.
Vestibulocochlear	VIII	Sensory	<i>Vestibular branch:</i> Sense of balance or equilibrium. <i>Cochlear branch:</i> Sense of hearing.
Glossopharyngeal	IX	Mixed	Produces the gag and swallowing reflexes. Taste (posterior third of the tongue).
Vagus	X	Mixed	Innervates muscles of throat and mouth for swallowing and talking. Other branches responsible for pressoreceptors and chemoreceptor activity.
Accessory	XI	Motor	Movement of the trapezius and sternocleidomastoid muscles. Some movement of larynx, pharynx, and soft palate.
Hypoglossal	XII	Motor	Movement of tongue for swallowing, movement of food during chewing, and speech.

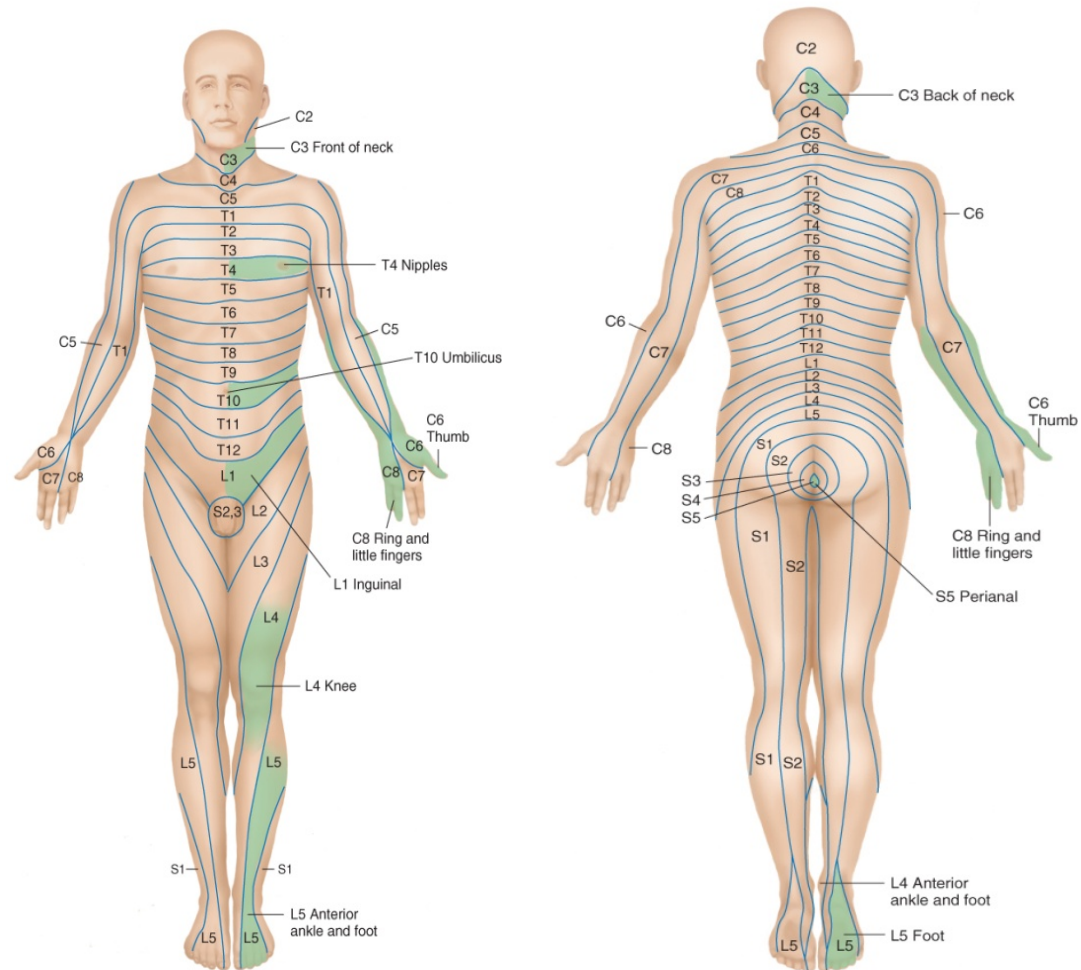
Peripheral Nervous System-Spinal nerves

- 31 pairs of spinal nerves
 - 8 pairs of cervical nerves
 - 12 pairs of thoracic nerves
 - 5 pairs of lumbar nerves
 - 5 pairs of sacral nerves
 - 1 pair of coccygeal nerves



SPINAL NERVES

Dermatome: band of skin innervated by the sensory root of a single spinal nerve



Common or Concerning Symptoms of the Nervous System

- Observing mental status, speech, and language
- Observing sensorium, memory, abstract thinking ability, speech, mood, emotional state, perceptions, thought processes, ability to make judgments

- Headache
- Dizziness or vertigo
- Weakness
- Numbness
- Loss of sensations
- Loss of consciousness
- Seizures
- Tremors or involuntary movements

Physical Assessment of the Neurologic System

- Testing cranial nerves
- Testing Motor function
- Testing Sensory function
- Testing Reflexes

(Always consider left to right symmetry)

Areas of the Neurologic System Assessment

- Testing cranial nerves

- I

- II

- III

- IV

- V

- VI

- VII

- VIII

- IX


- X

- XI

- XII

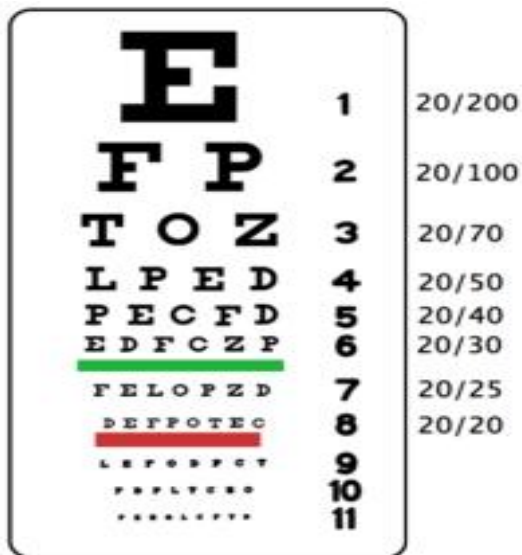
I. Olfactory: smell

- Client both eyes and one naris are closed
- Place a strong smelling item under each nostril individually and ask the person to identify it.



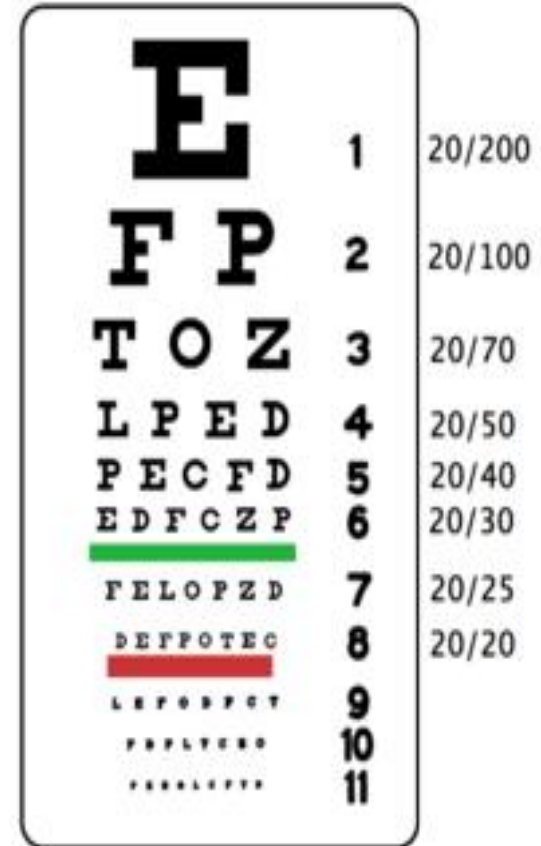
II. Optic: vision

- Visual acuity
 - Distance/Central vision: Snellen eye chart
 - Near vision (hand-held card)
- Examine the Optic Fundi by using the Ophthalmoscope



Eyes – Techniques of Examination


- Visual acuity
 - Distance/Central vision: Snellen eye chart;
position patient 20 feet (6 meters) from the chart
 - Patients should wear glasses if needed
 - Test one eye at a time



Eyes – Techniques of Examination

- Visual acuity
 - Near vision: use (Jaeger or Rosenbaum chart (hand-held card))
 - can also use to test visual acuity at the bedside
 - hold 14 inches (about 30 cm) from patient's eyes

Jaeger chart

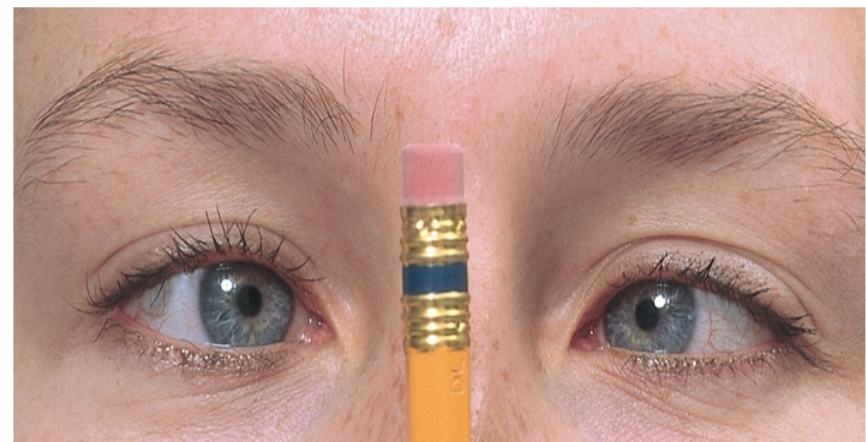
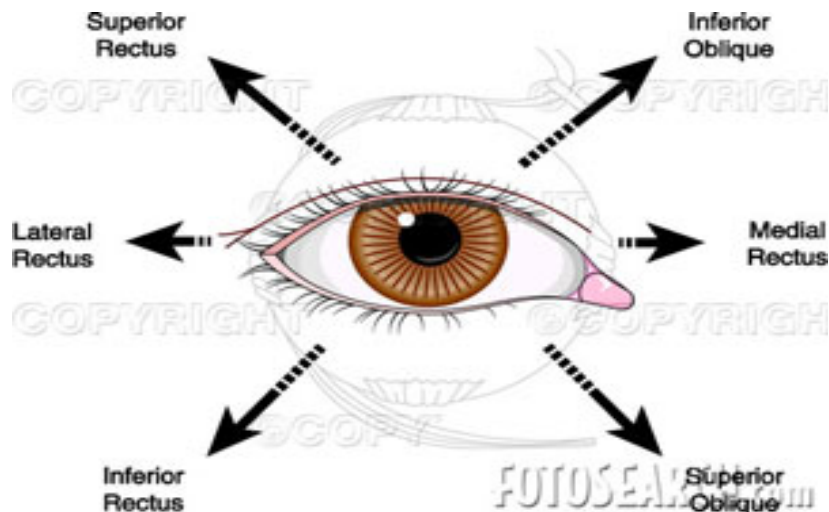


Rosenbaum chart



III. Oculomotor IV. Trochlear VI. Abducens

- Test Extraocular Movements
- Test direct and consensual pupillary reaction to light
- Accommodation

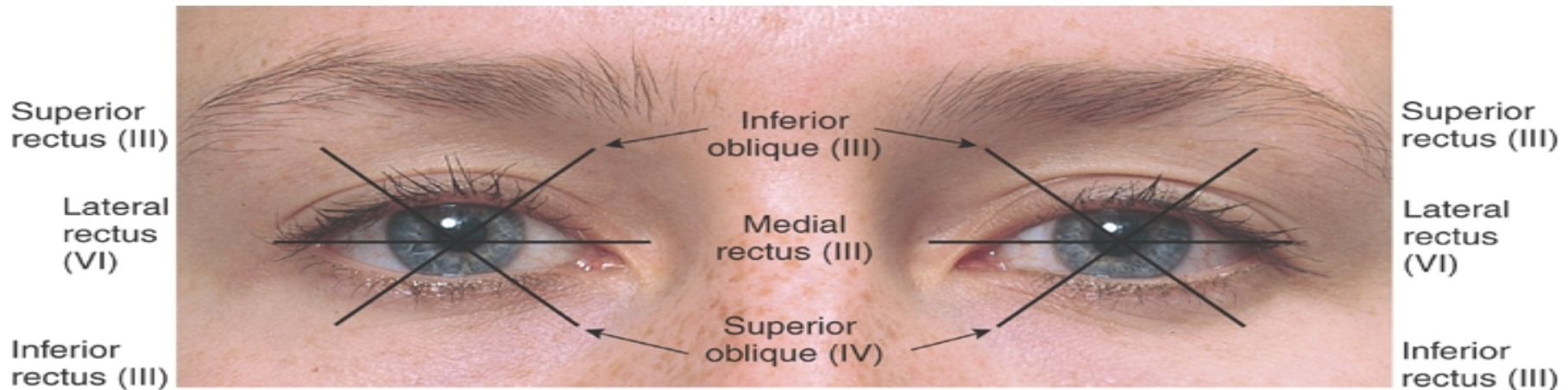


The Near Reaction (B)

Copyright © 2007 Lippincott Williams & Wilkins. Instructor's Resource CD-ROM to Accompany Bickley's Bates' Guide to Physical Examination and History Taking, ninth edition.

Eyes – Techniques of Examination

- Extraocular movements/six cardinal directions of gaze/wagon wheel method
- The client must keep the head still while following a pen that you will move in several directions to form a star in front of the client's eyes.
- Always return the pen to the center before changing direction.



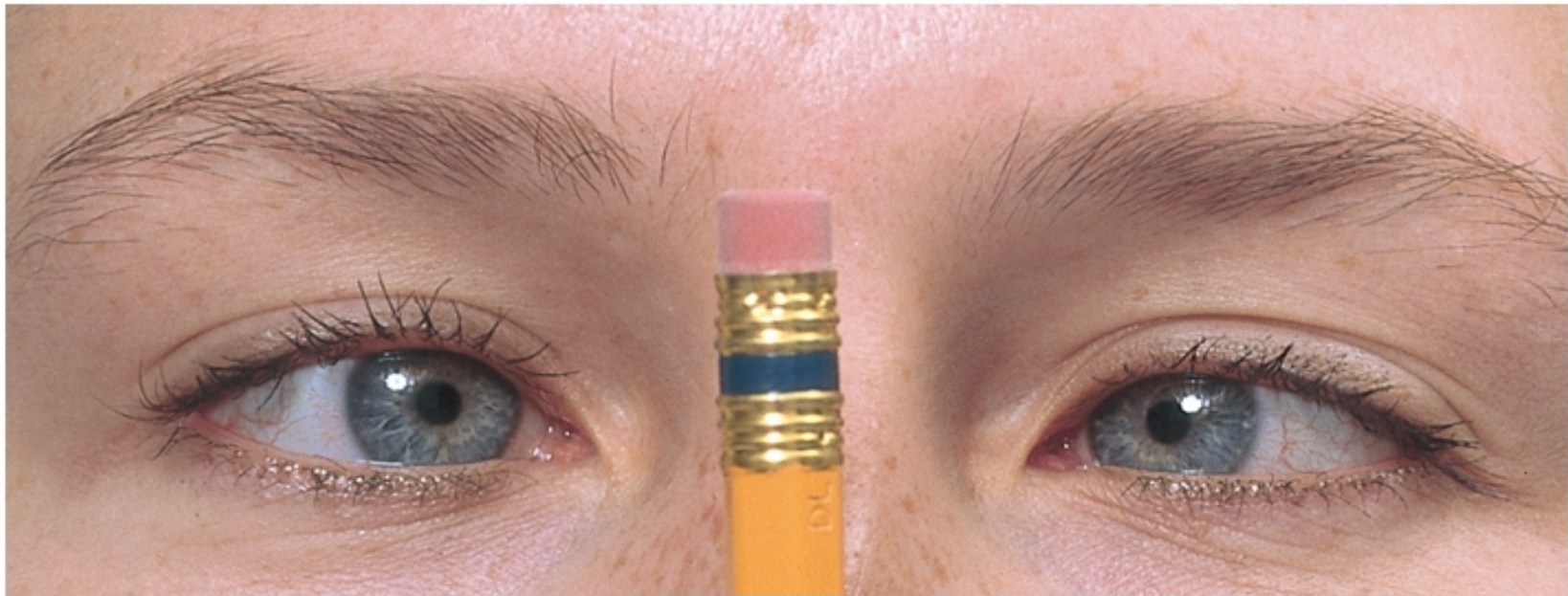
Cardinal Directions of Gaze

Copyright © 2007 Lippincott Williams & Wilkins. Instructor's Resource CD-ROM to Accompany Bickley's Bates' Guide to Physical Examination and History Taking, ninth edition.

Eyes – Techniques of Examination

- Accommodation

An object held about 10 cm from the client's nose

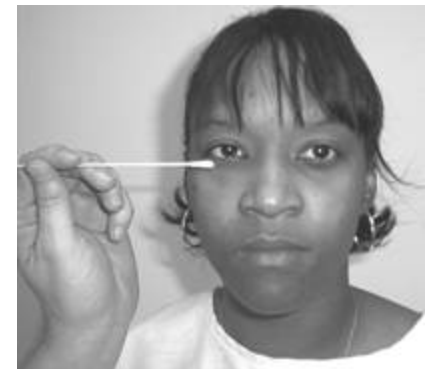
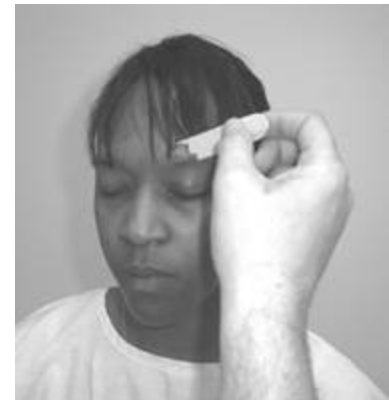
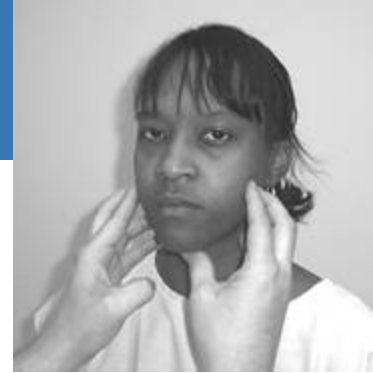The Near Reaction (B)

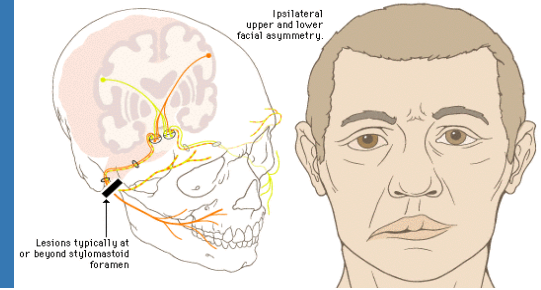
Copyright © 2007 Lippincott Williams & Wilkins. Instructor's Resource CD-ROM to Accompany Bickley's Bates' Guide to Physical Examination and History Taking, ninth edition.

V. Trigeminal

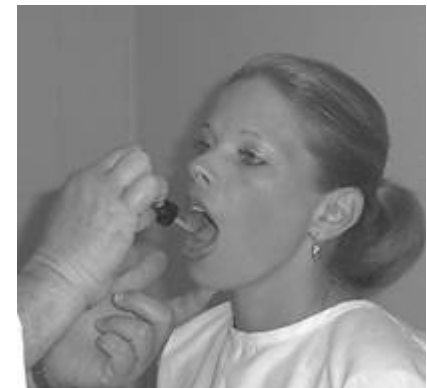- Bilaterally palpate temporal and masseter muscles while patient clenches teeth
- (Sensation) Ask client to closed his eyes and test forehead, each cheek, and jaw on each side for sharp or dull (use a cotton swab) sensation. Direct the client to say 'now' every time the cotton is felt.
- (Reflex) With the individual's eyes open and looking upward, the practitioner takes a strand of cotton, approaches the cornea from the side, and touches it with the cotton. This should initiate a blink response. Both eyes should be tested independently.



VII. Facial



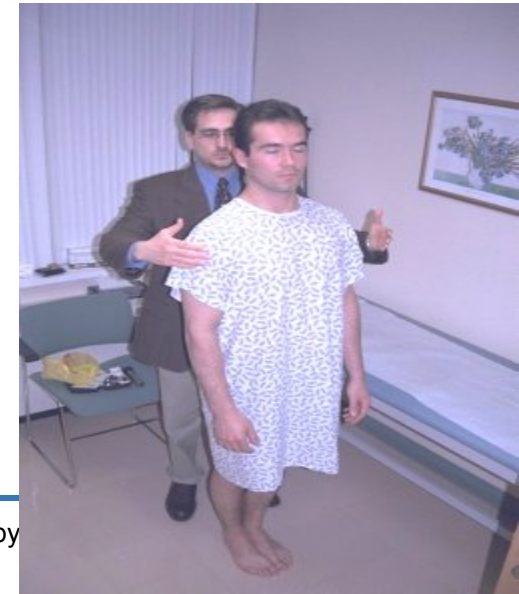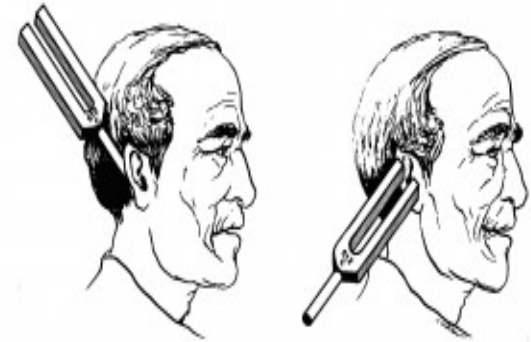
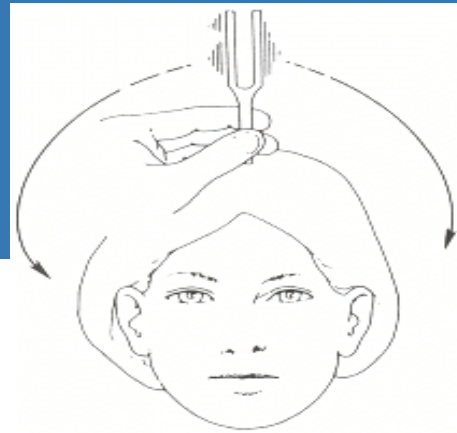
- Ask the client to close both eyes and keep them closed. Try to open them by retracting the upper and lower lids simultaneously and bilaterally.
- Ask patient to raise eyebrows, show teeth, grimace, smile, puff both cheeks (Assess face for asymmetry, abnormal movements)
- Use the sweet, salty, sour and bitter items to test taste (Between each solution the mouth needs to be rinsed with water)





VIII. Acoustic

- Weber Test (by using a tuning fork).
- Rinne test: to compares air and bone conduction
- Romberg test: Ask the patient to remain still and close their eyes (for about 20 seconds).

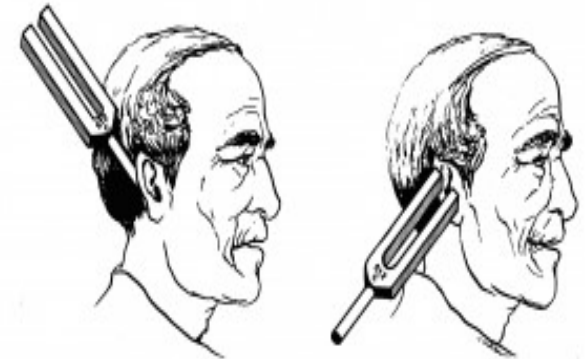


Ears – Hearing acuity

Air and bone conduction (AC and BC)

— Rinne

- Compare time of air vs. bone conduction
- Place the base of the tuning fork on the client's mastoid process- and note the number of seconds.
- Then move the fork in front the external auditory meatus (1-2 cm)



IX. Glossopharyngeal

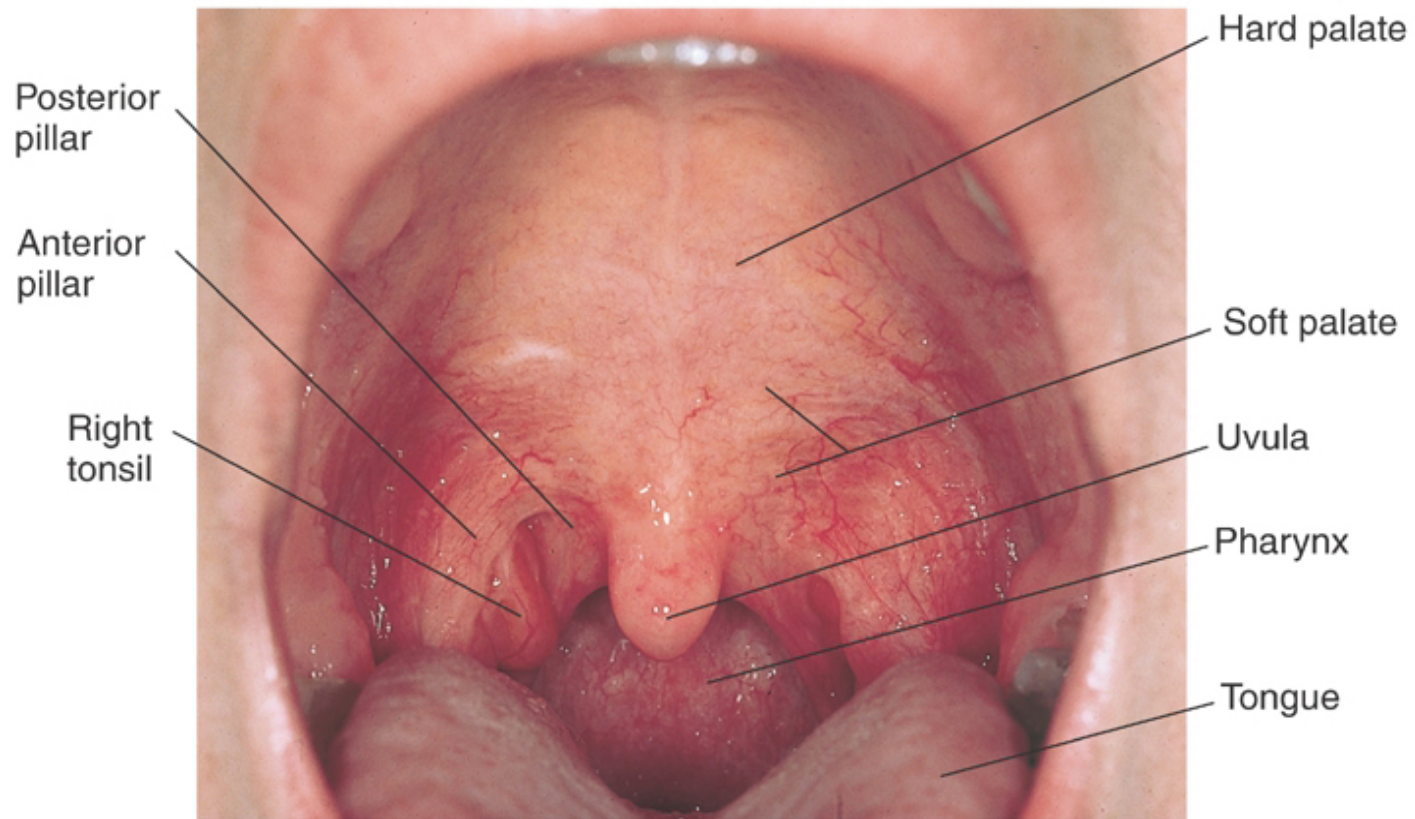
X. Vagus

- Ask the client to open the mouth, depress the client's tongue with the tongue blade, ask the client to say "ah". Usually, the soft palate raises and the uvula remains in the midline
- Observe the individual swallowing.
- Test gag reflex, warning patient first.




LX. GLOSSOPHARYNGEAL X. VAGUS

Ask the client to open the mouth, depress the client's tongue with the tongue blade, ask the client to say "ah". Usually, the soft palate raises and the uvula remains in the midline



Above and Behind the Tongue

X1. Spinal Accessory



- Test the Trapezius muscle: have the client shrug the shoulders while you resist with your hands
- Ask the client to try to touch the right ear to the right shoulder without raising the shoulder. Repeat with the left shoulder



XII. Hypoglossal

- Ask patient to protrude tongue and move it side to side. Assess for symmetry, atrophy.



Areas of the Neurologic System Assessment

- Motor function
 - Observation of gait and balance
 - Administration of the Romberg test
 - Administration of the finger-to-nose test
 - Observation of rapid alternating action movements

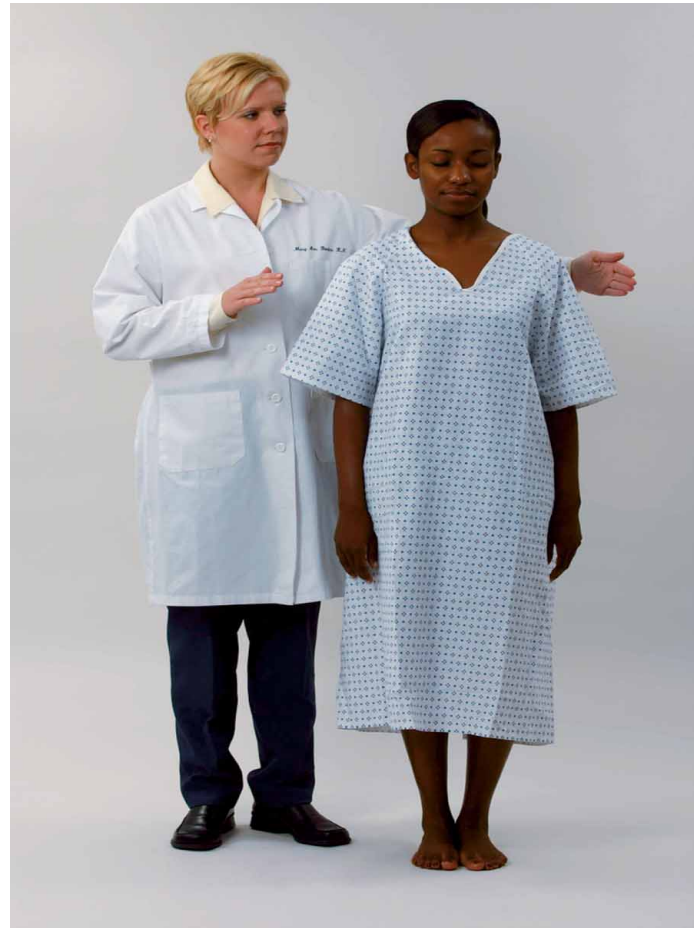Observation of gait and balance

Ask the client to walk across the room and return



Romberg's test for balance.

Ask the patient to remain still and close their eyes (for about 20 seconds).



Finger-to-nose test.

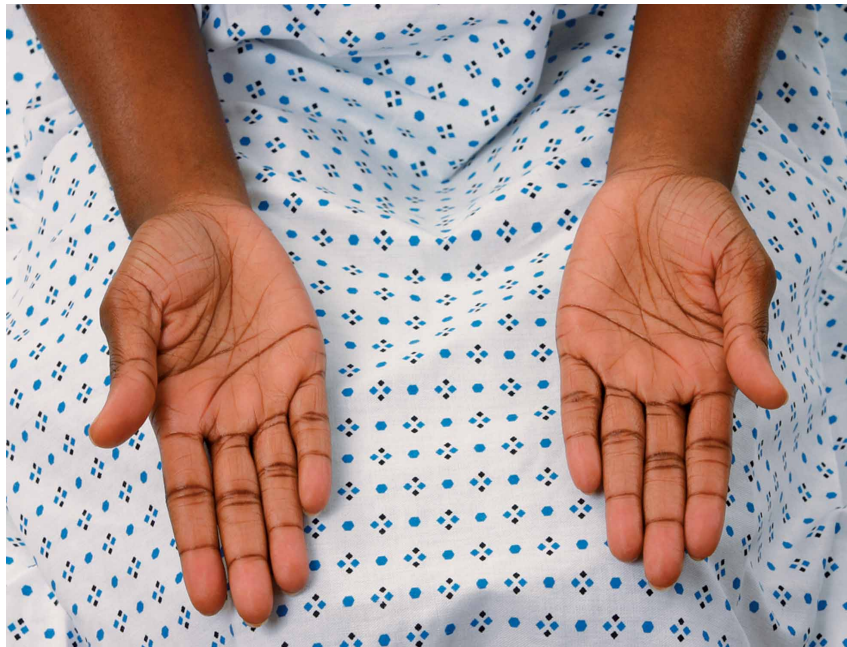- Ask the client to extend both arms from the sides of the body
- ask the client to keep both eyes open
- ask the client to touch the tip of the nose with right index finger, and then return the right arm to an extended position.
- ask the client to touch the tip of the nose with left index finger, and then return the left arm to an extended position.
- Repeat the procedure several times.
- Ask the client to close both eyes and repeat the alternating movements



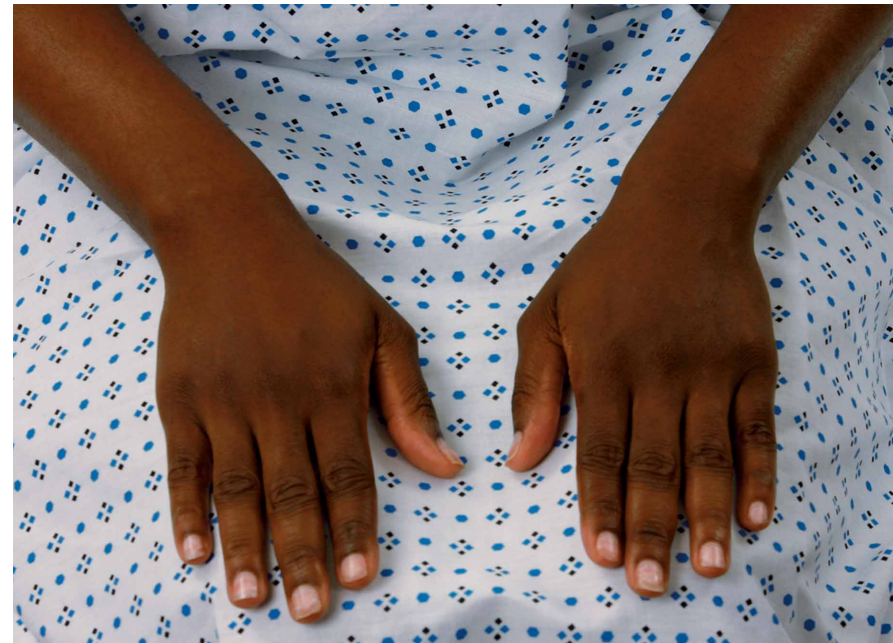Observation of rapid alternating action movements

- Ask the client to sit with the hands placed palms down on the thighs.
- Ask the client to return the hands palms up.
- Ask the client to return the hands to a palms-down position.
- Ask the client to alternate the movements at a faster pace.

Testing rapid alternating movement, palms up.
down.



Testing rapid alternating movement, palms down.

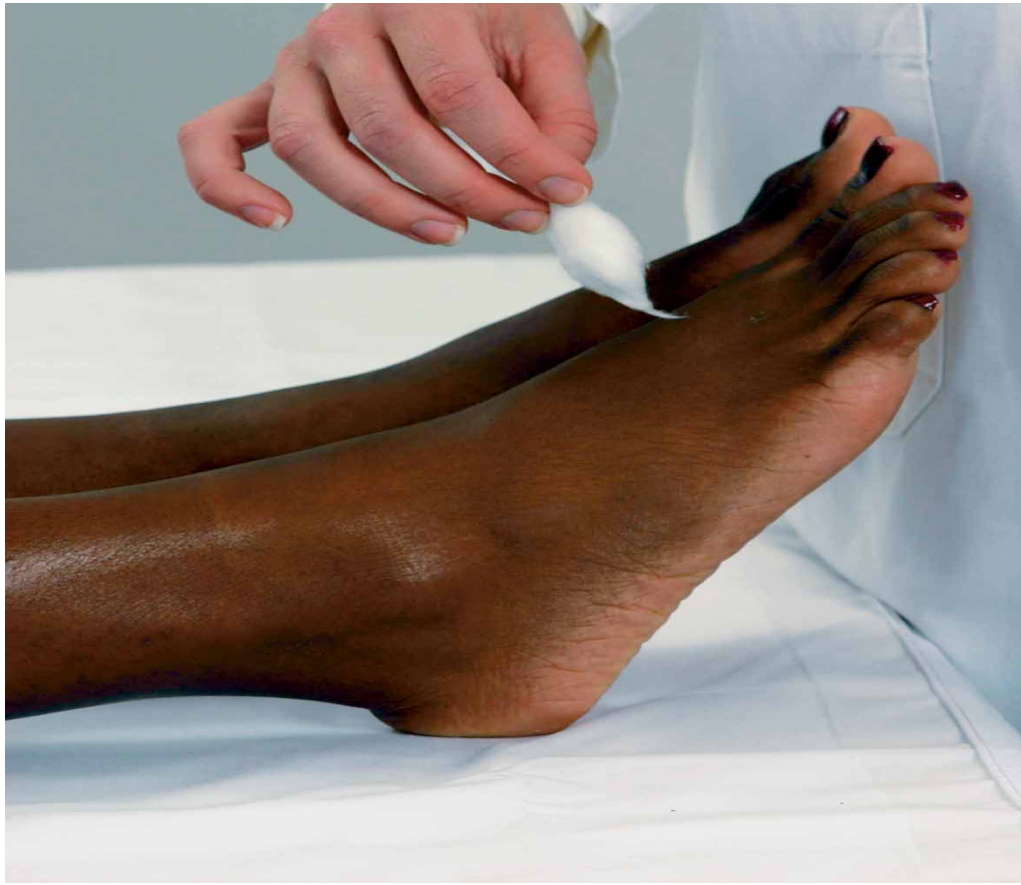

Areas of the Neurologic System Assessment

- Sensory function
 - Observation of light touch identification
 - Sharp, dull determination
 - Stereognosis
 - Graphesthesia (Number identification)

-Evaluation of light touch.

- Use wisp of cotton to touch the skin lightly on both sides simultaneously.
- Test several areas on both the upper and lower extremities.
- Ask the patient to tell you if there is difference from side to side or other "strange" sensations.

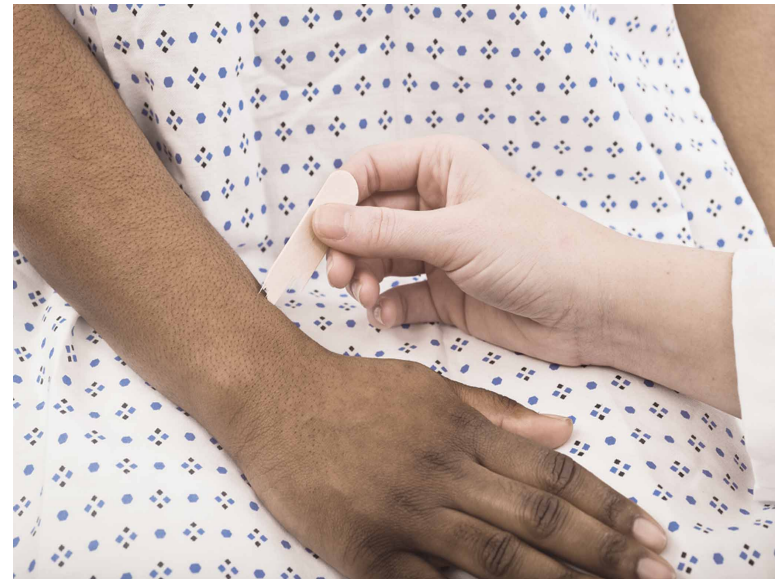
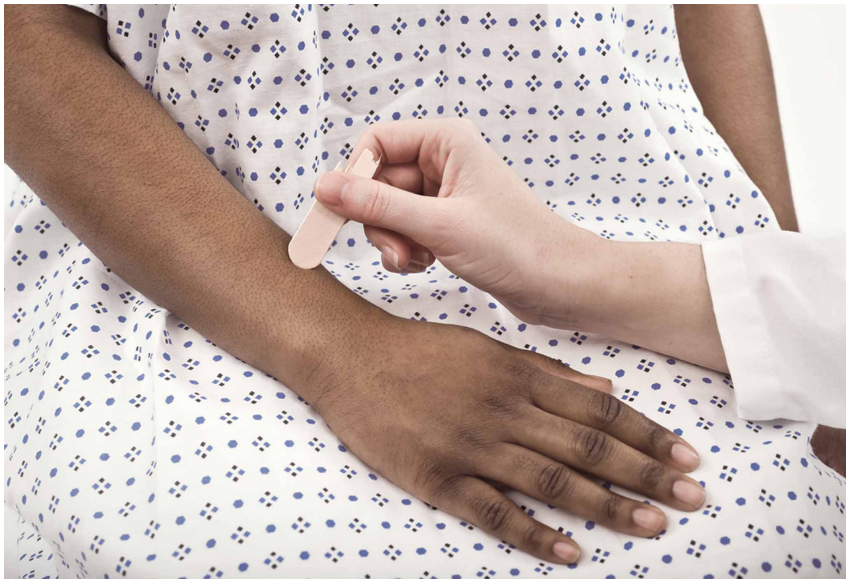
Testing the client's ability to identify sharp sensations.

- Ask the client to say “sharp” or “dull” when something sharp or dull is felt on the skin.
- Touch the client using random locations.


Testing the client's ability to identify dull sensations

Testing the client's ability to identify sharp sensations



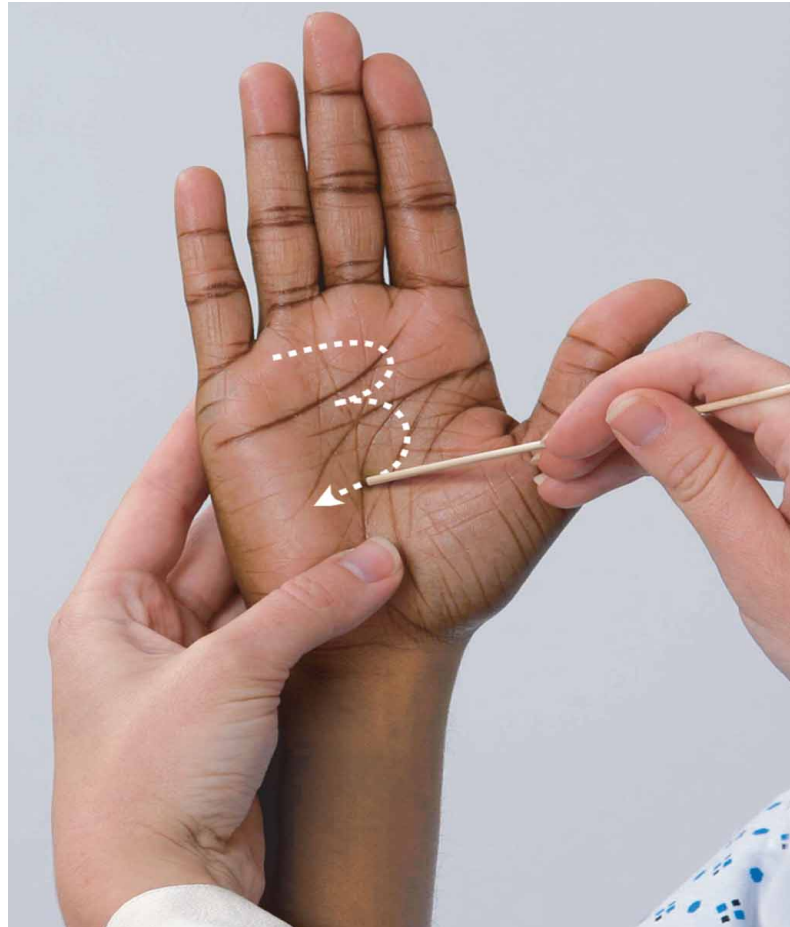
-Testing stereognosis using a coin

- Use as an alternative to graphesthesia.
- Place a familiar object in the patient's hand (coin, paper, pencil, etc.).
- Ask the patient to tell you what it is.



-Testing graphesthesia (Number identification)

- With the blunt end of a pen or pencil, draw a large number in the patient's palm.
- Ask the patient to identify the number.

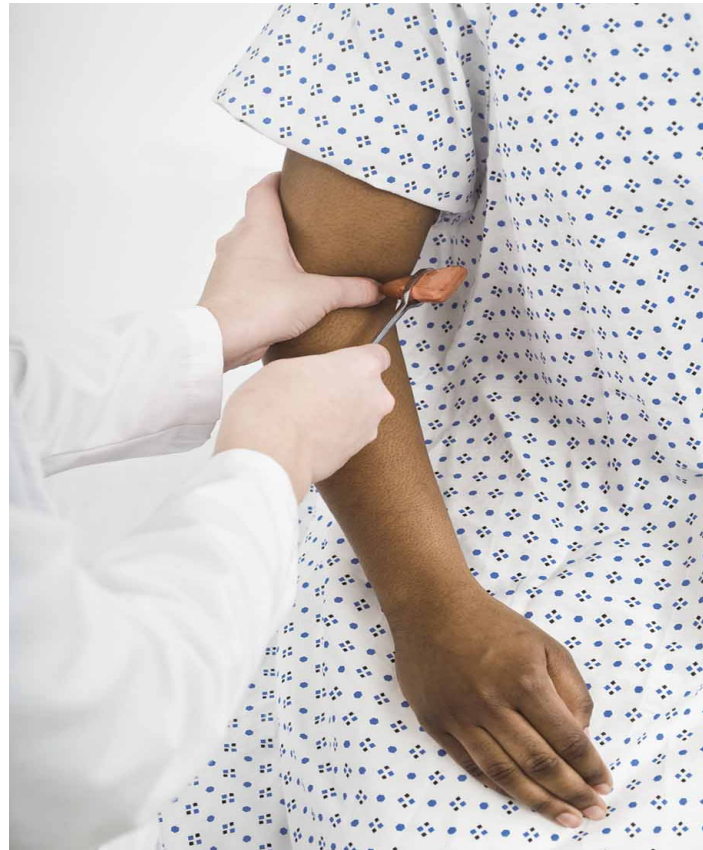


Areas of the Neurologic System Assessment

- **Reflexes** (Stimulus-response activities of the body.)
 - Biceps
 - Triceps
 - Brachioradialis
 - Patellar (knee)
 - Achilles
 - Plantar (Babinski).
 - Abdominal

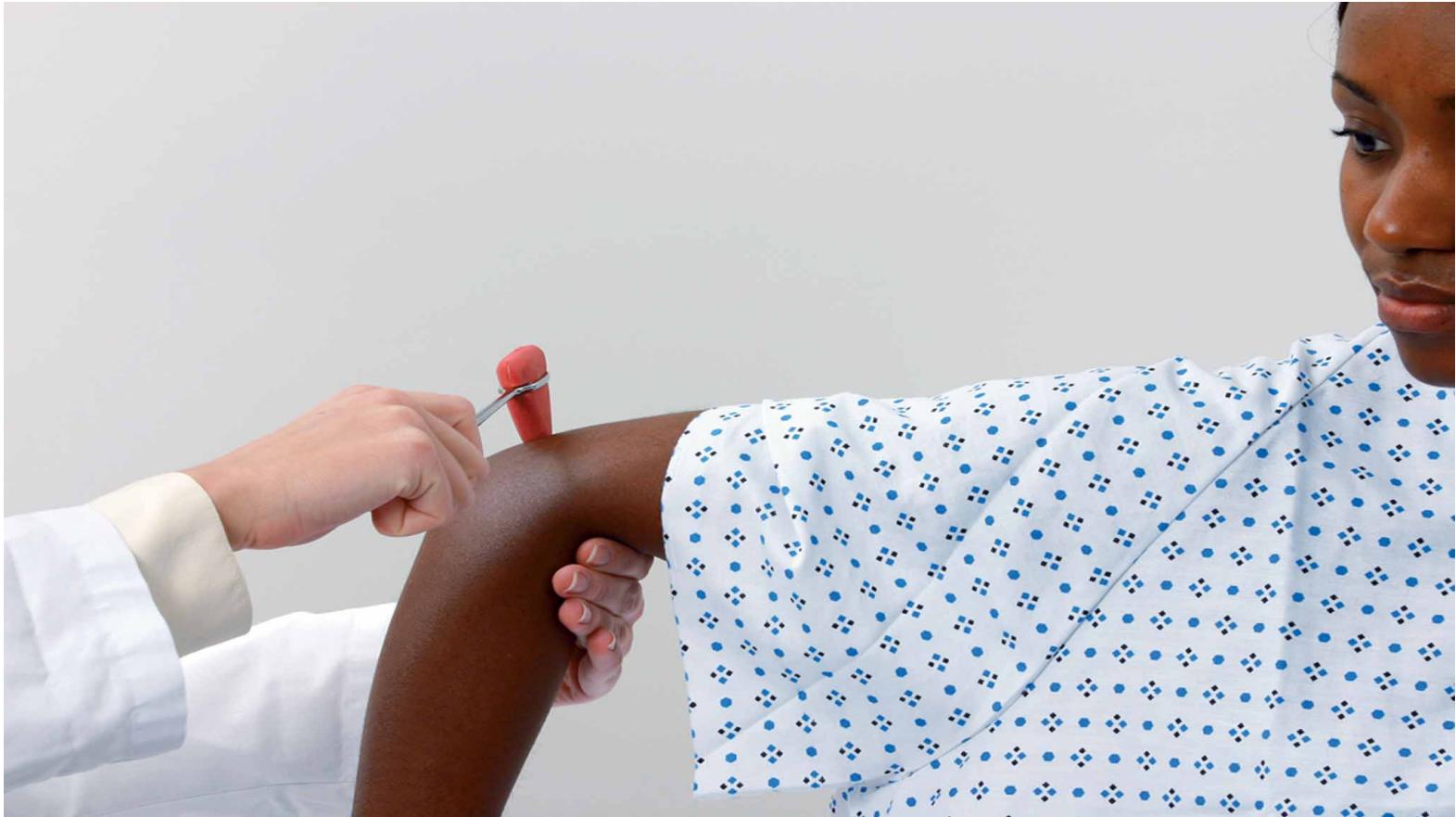
Testing the biceps reflex.

- The patient's arm should be partially flexed at the elbow with the palm down.
- Place your thumb or finger firmly on the biceps tendon.
- Strike your finger with the reflex hammer.
- look for contraction of the biceps muscle and slight flexion of the forearm.



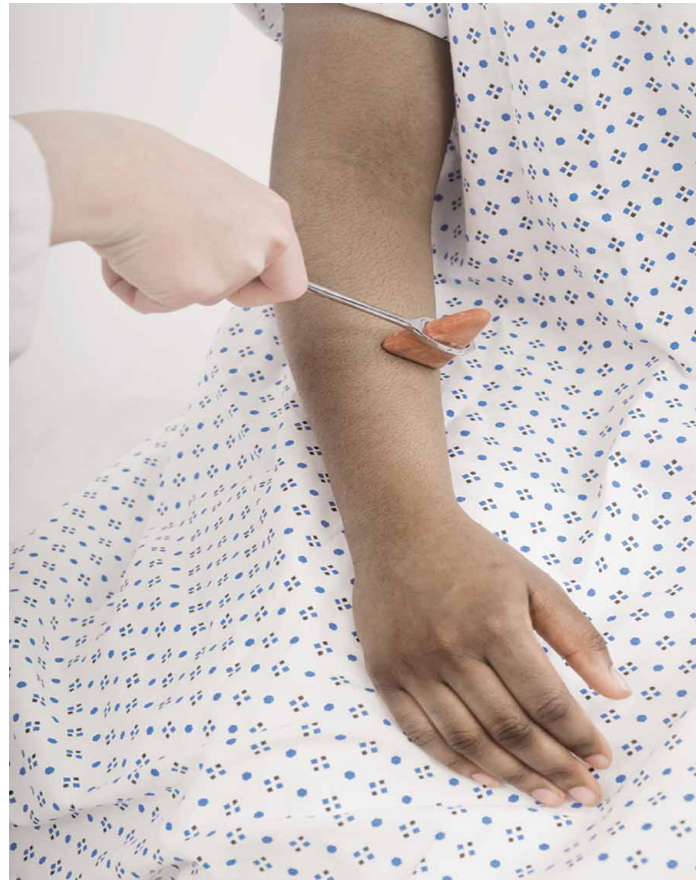Testing the triceps reflex.

- Support the upper arm and let the patient's forearm hang free.
- Strike the triceps tendon above the elbow with the broad side of the hammer.
- observe contraction of the triceps muscle with extension of the lower arm.



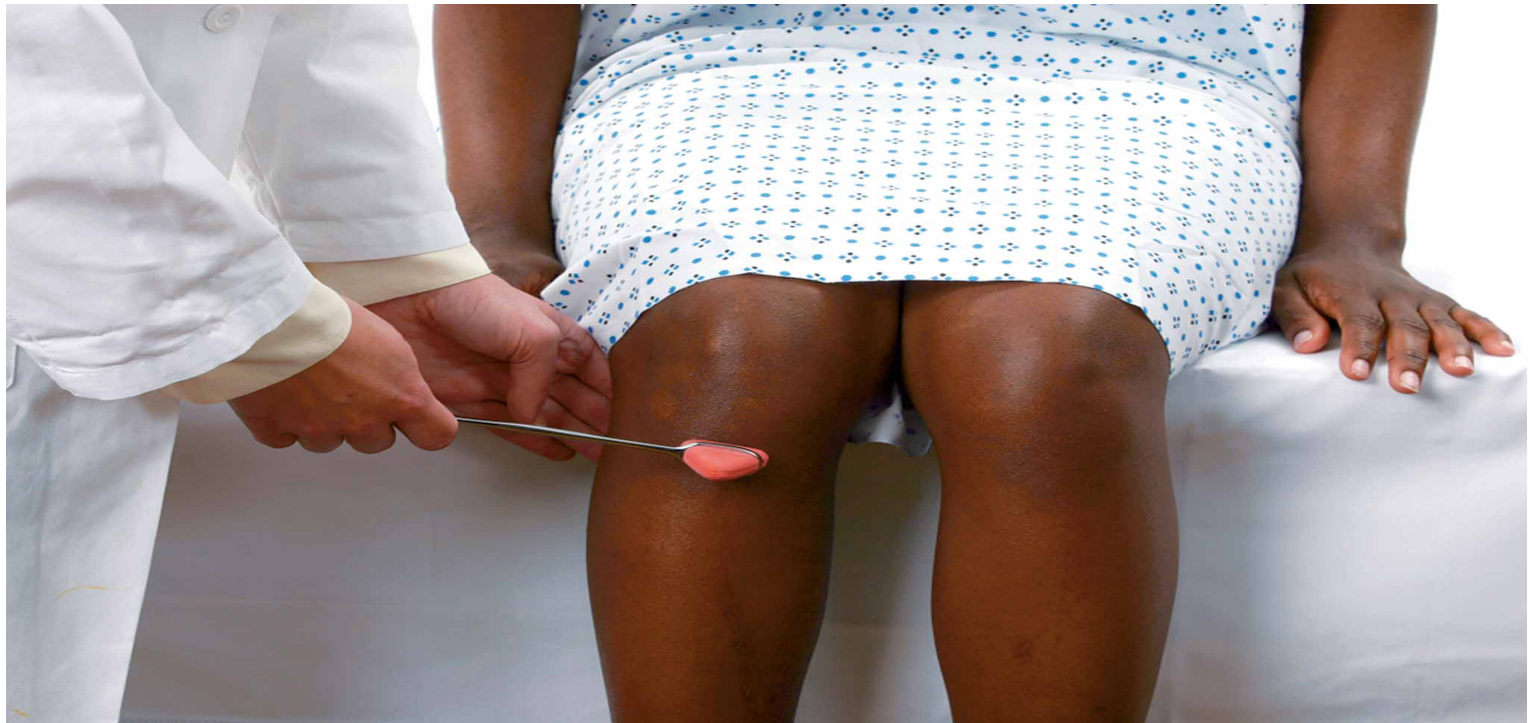Testing the brachioradialis reflex.

- Have the patient rest the forearm on the abdomen or lap.
- Strike the radius about 1-2 inches above the wrist.
- Watch for flexion and supination of the forearm.



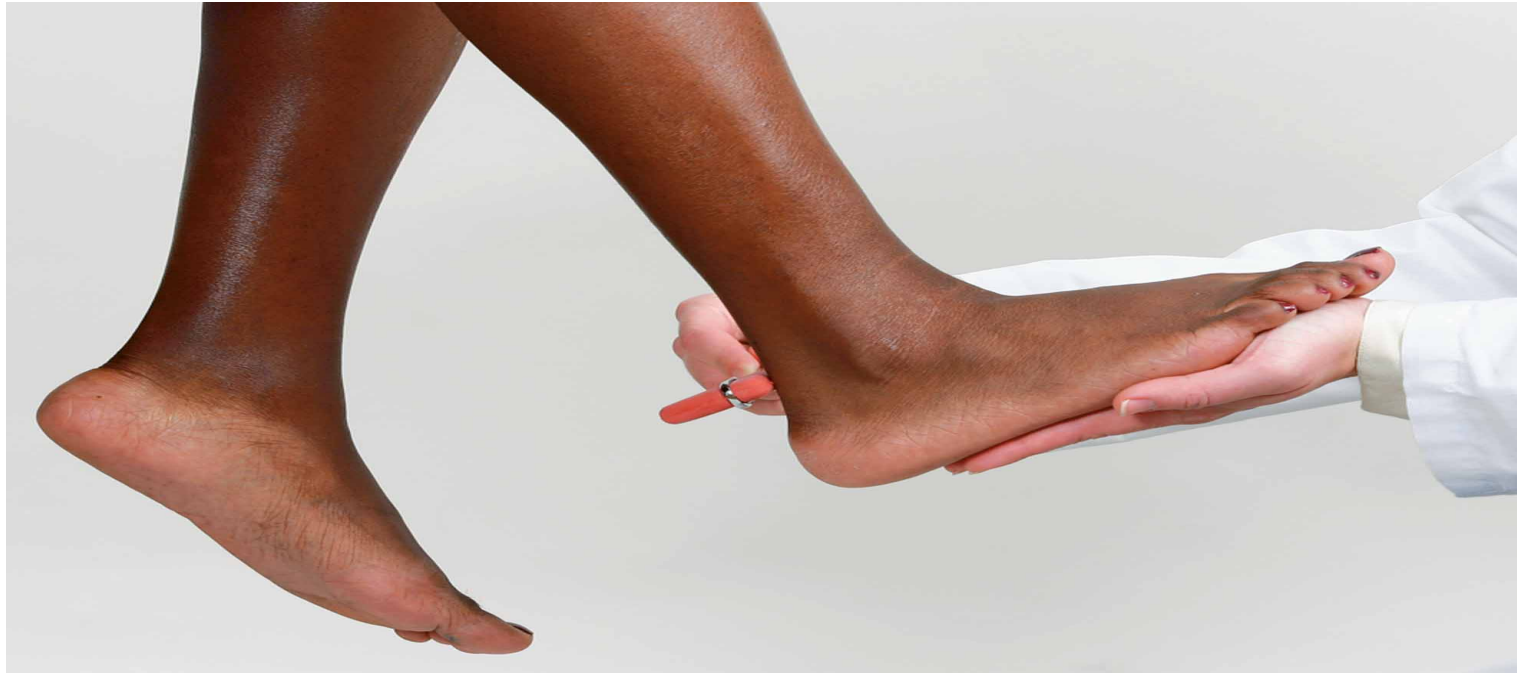Testing patellar (knee) reflex, client in a sitting position.

- Have the patient sit with the knee flexed.
- Strike the patellar tendon just below the patella.
- Note contraction of the quadriceps muscle and extension of the knee.



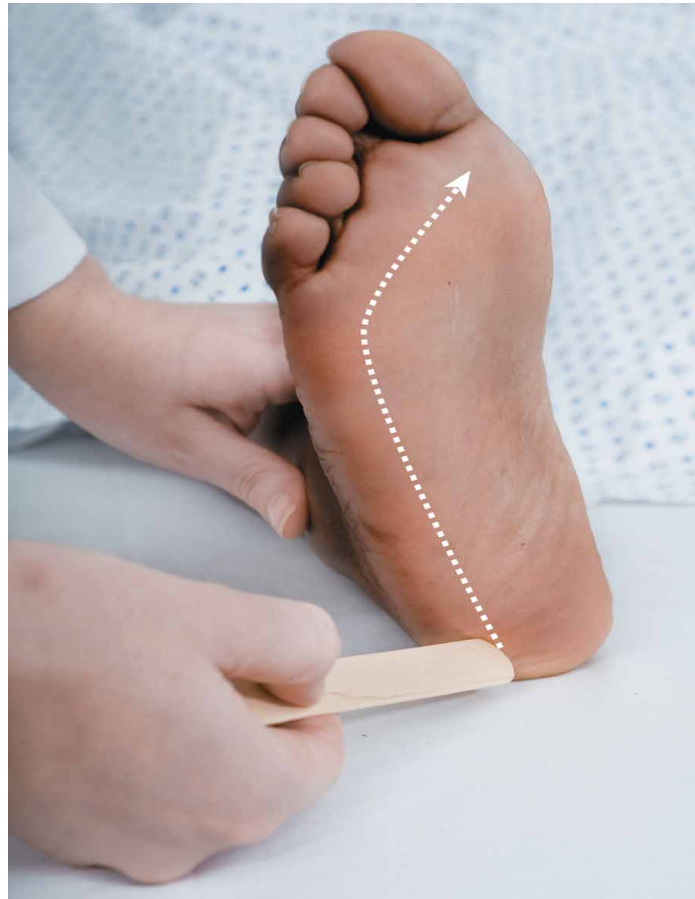Testing the Achilles tendon reflex with client in a sitting position.

- Dorsiflex the foot at the ankle.
- Strike the Achilles tendon.
- Watch and feel for plantar flexion at the ankle.



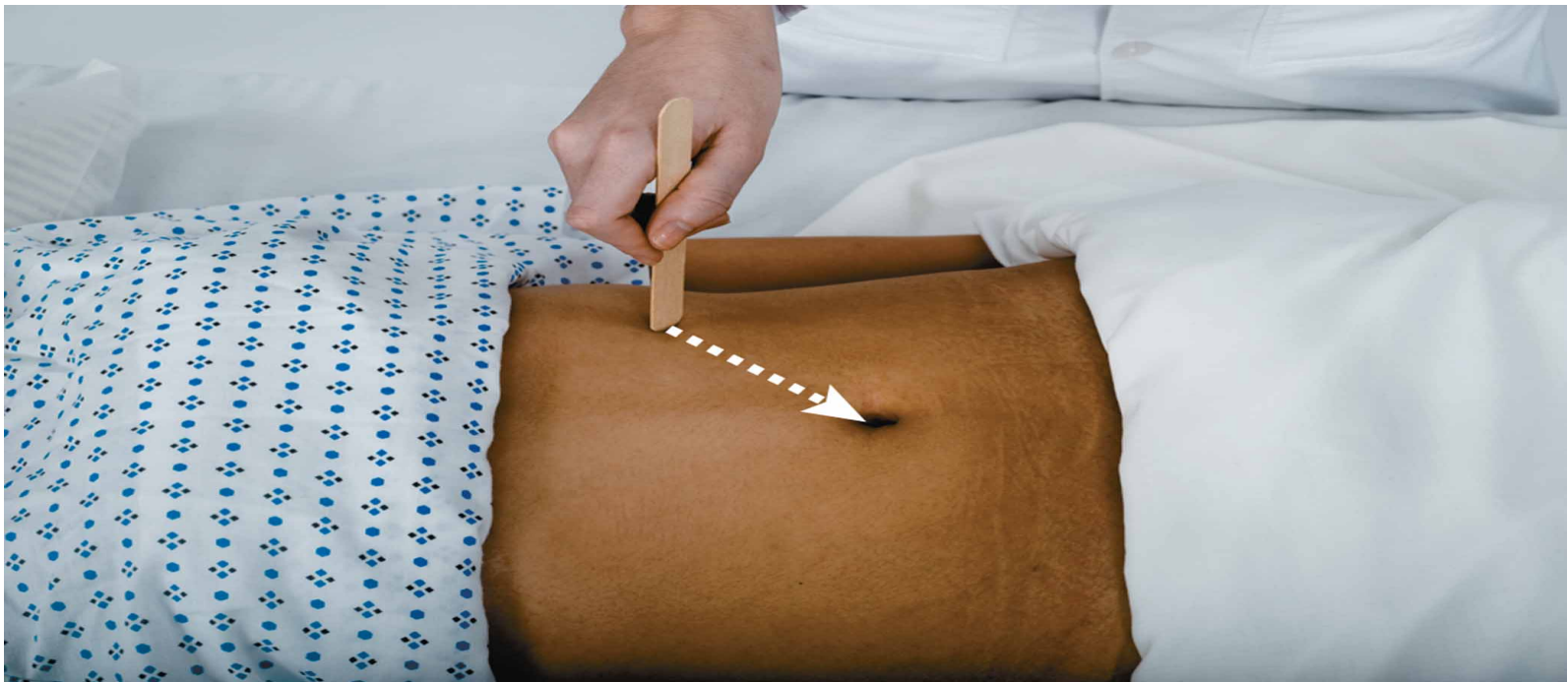
Testing the plantar reflex (Babinski).

- Stroke the lateral aspect of the sole of each foot with the end of a reflex hammer or key.
- Observe for planter flexion of the foot .



Abdominal reflex testing pattern.

- Use a blunt object such as a key or tongue blade.
- Stroke the abdomen lightly on each side in an inward and downward direction.
- Note the contraction of the abdominal muscles and deviation of the umbilicus towards the stimulus.



REFLEXES: SCALE FOR GRADING

Reflexes are usually graded on a 0 to 4+ scale

4+ Very brisk, hyperactive, with clonus (rhythmic oscillations between flexion and extension)

3+ Brisker than average; possibly but not necessarily indicative of disease

2+ Average; normal

1+ Somewhat diminished; low normal

0 No response

Areas of the Neurologic System

Assessment-Additional assessments

GLASGOW COMA SCALE

BEST EYE-OPENING RESPONSE

- 4 = Spontaneously
- 3 = To speech
- 2 = To pain
- 1 = No response

(Record “C” if eyes closed by swelling)

BEST MOTOR RESPONSE to painful stimuli

- 6 = Obeys verbal command
- 5 = Localizes pain
- 4 = Flexion—withdrawal
- 3 = Flexion—abnormal
- 2 = Extension—abnormal
- 1 = No response

(Record best upper limb response)

BEST VERBAL RESPONSE

- 5 = Oriented × 3
- 4 = Conversation—confused
- 3 = Speech—inappropriate
- 2 = Sounds—incomprehensible
- 1 = No response

(Record “E” if endotracheal tube in place, “T” if tracheostomy tube in place)